

## Article information

DOI: 10.63475/yjm.v5i1.0335

### Article history:

Received: 13 March 2026

Accepted: 14 March 2026

Published: 17 April 2026

### Correspondence to:

Dhaniwala S. Nareshkumar

Email: [nsdhaniwala@gmail.com](mailto:nsdhaniwala@gmail.com)

ORCID: [000-0003-2640-4970](https://orcid.org/000-0003-2640-4970)

### How to cite this article

Dhaniwala NS, Dhaniwala MN, Dhaniwala AM, Lohiya AA. The hidden fungus: Mycetoma unveiled in a young adult's great toe. *Yemen J Med*. Published online April 17, 2026. doi: 10.63475/yjm.v5i1.0335:1-4.

### Copyright License: © 2026 authors.

This scholarly article is disseminated in accordance with the provisions of the Creative Commons Attribution License, thereby permitting unrestricted utilization, distribution, or reproduction across any medium, provided that credit is given to the authors and the journal

## Case Report

# The Hidden Fungus: A Case of Mycetoma Unveiled in a Young Adult's Great Toe

Dhaniwala Nareshkumar S.<sup>1</sup>, Dhaniwala Mukund N.<sup>2</sup>, Dhaniwala Aditi M.<sup>3</sup>, Lohiya Ashutosh A.<sup>4</sup>

1 Professor, Department of Orthopaedics, MS Orthopaedics, Jawaharlal Nehru Medical College, Datta Meghe Institute of Higher Education and Research, Sawangi Meghe, Wardha, India

2 Consultant, Dhaniwala Orthopaedics and Dental Clinic, Nanded, India

3 Consultant, Dhaniwala Orthopaedics and Dental Clinic, Nanded, India

4 Senior Resident, Department of Orthopaedics, MS Orthopaedics, Jawaharlal Nehru Medical College, Datta Meghe Institute of Higher Education and Research, Sawangi Meghe, Wardha, India

### ABSTRACT

Mycetoma is a chronic granulomatous infection affecting subcutaneous tissues and bones, caused by either fungi or bacteria. Its varied causes and clinical manifestations often make diagnosis and treatment challenging. Eumycetoma, specifically, is a deep fungal infection of the skin and underlying tissue caused by filamentous fungi. We report a case of Eumycetoma in a healthy, immunocompetent 22-year-old male who presented with swelling and limited movement in his right big toe. On examination, a non-tender 3 cm × 2 cm × 1 cm swelling was observed on the dorsal side of the toe, leading the treating clinician to initially suspect tenosynovitis. An excisional biopsy was performed under spinal anesthesia, revealing multiple pockets within the subcutaneous tissue containing black granules. Further microbiological and histopathological analysis confirmed Eumycetoma. Treatment was started with itraconazole 200 mg twice daily for 6 months. At a 15-month follow-up, the patient remained symptom-free, with normal walking ability and no issues wearing regular shoes. There was no sign of recurrence or any neurovascular complications.

**Key words:** Mycetoma, Eumycetoma, Actinomycetoma, hyphae, granules, histopathological examination

### INTRODUCTION

Mycetoma is a chronic, mutilating, and disabling infection of the skin and underlying tissues, including bone, caused by fungi or bacteria. The disease caused by true saprophytic fungi is called Eumycetoma, while the one caused by bacteria is labelled as Actinomycetoma.

Mycetoma is seen in farm and field workers who sustain injuries to the foot, hand, and other parts of the body. These are common in people aged 20 to 40 years. Eumycetoma is a slow progressive condition, as against Actinomycetoma, which is relatively rapid and inflammatory in course. Lymphatic spread and early bone invasion are seen in Actinomycetoma, while bone invasion is delayed and lymphatic spread is occasional in Eumycetoma. In the advanced stage, there occurs discharge of grains which are coarse and black in Eumycetoma and fine, smaller, and yellowish white in Actinomycetoma. [1]

Inoculation of the causative agent occurs during contact with soil and thorns during manual work. [2] A nonspecific inflammatory response is followed by slow progression

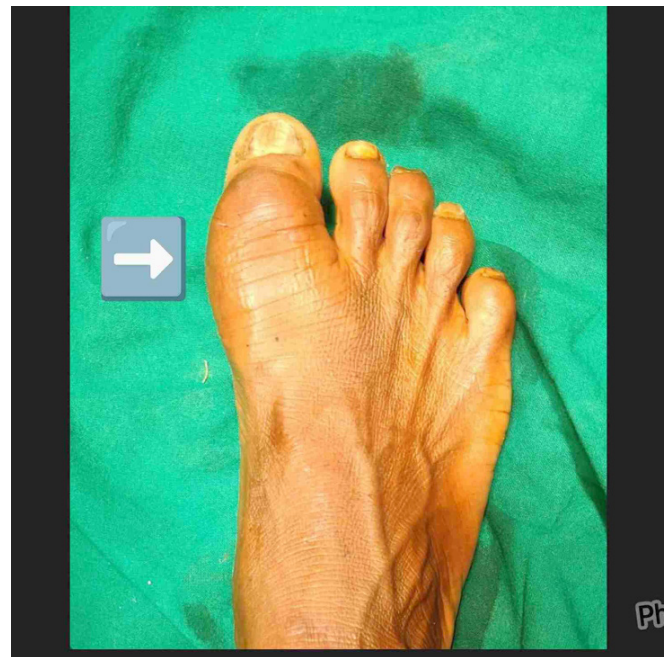from acute to chronic phase involving deeper tissue such as fascia, muscles, and finally bone, developing multiple sinuses, causing thickening of tissues and developing papule/nodule/abscess or induration in the nearby area. The interval between initial infection and manifestation of disease may vary from 3 months to 50 years. [3] Involved skin may become hypo- or hyperpigmented. Swelling may burst along fascial planes, discharging fluid, rich in grains. Episodes of breakdown and healing are repeated, making the part edematous, enlarged, nodular, deformed, and functionless. Pain is an uncommon symptom reported only in 15% cases. [4] No known vector or animal reservoir is established.

The report herein describes a case of Eumycetoma in a young adult presenting as a case of Chronic tenosynovitis of the great toe extensor tendon. This case is presented to emphasize that mycetoma should be considered in patients showing chronic synovitis or tenosynovitis in the hands or feet, even when there are no visible sinuses or granule discharge. Early surgical intervention is crucial, and diagnosis should be confirmed through appropriate microbiological testing.

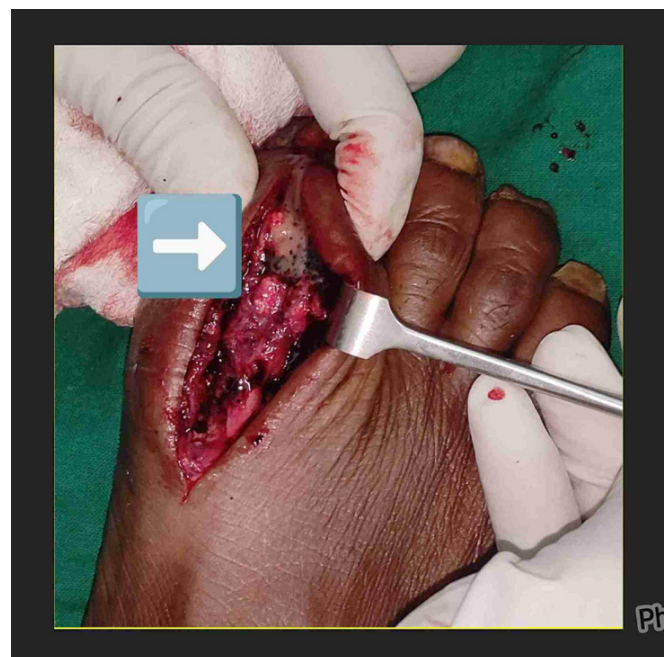
### CASE REPORT

A 22-year-old male patient, a farm laborer by occupation, presented with the chief complaint of swelling of the right great toe for 2 years. The swelling started spontaneously without any obvious trauma or thorn prick and slowly increased in size. There was no history of pain or fever at any time. The swelling caused difficulty in wearing foot wear due to which the patient reported to the hospital. There is a history of a slight increase in swelling with routine activities and a decrease with rest. There was no history of similar swelling anywhere in the body or any important medical event.

Examination revealed a non-tender enlargement of size 3 cm × 2 cm × 1 cm on the right great toe on the dorsal aspect with slightly stretched skin. The swelling extended proximally from the metatarsophalangeal joint (MTP) distally to 1 cm proximal to the nail bed (**Figure 1**). There was no local rise in temperature and no sinuses. The subcutaneous tissue was thickened, and the movements of MTP and Proximal Interphalangeal (PIP) joints were restricted. Clinically, the case was diagnosed as tenosynovitis of the extensor hallucis longus (EHL) tendon because the swelling was along the EHL tendon and around the MTP of the great toe, and moved with its movement. X-rays of the toe showed soft tissue swelling without any changes in the bones. The swelling was aspirated, yielding a little fluid. The cytology showed polymorphs, lymphocytes, and oval polygonal mononuclear cells showing vacuoles, suggesting chronic tenosynovitis. His blood investigations were within normal range and did not show any abnormal cells. The patient was taken up for excisional biopsy of the swelling under spinal anesthesia, through a 4 cm. long dorsomedial incision. The subcutaneous plane had multiple pockets, the dissection of which yielded black grains (**Figure 2**). The sheath of the EHL tendon was thickened in its course. After due exposure, the thickened tissues were excised, and all granules were removed carefully. The bones, joints, and EHL did not have any infiltration by grains or abnormal tissues. Closure was done in two layers after thorough irrigation of the area. The excised tissue was sent for histopathology, and the black grains were submitted for fungus examination. Wet KOH-mounted grains showed




**Figure 1:** Clinical picture of the involved foot showing the metatarsophalangeal joint area of the great toe.



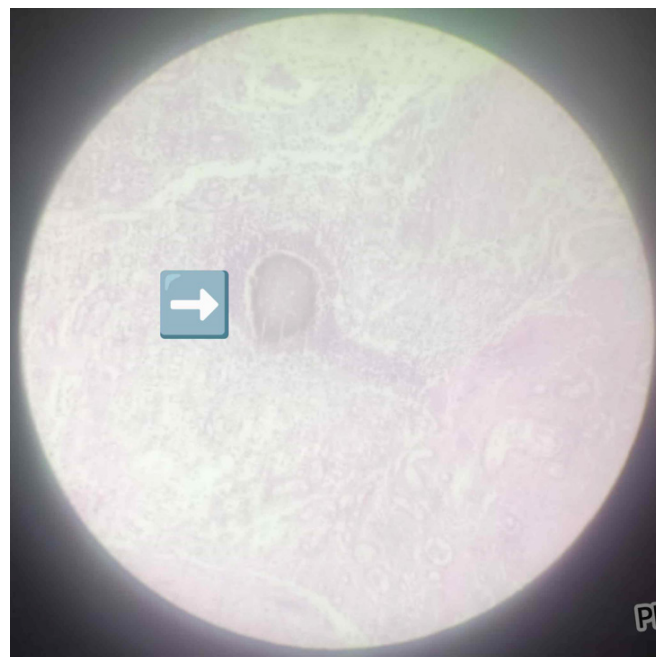**Figure 2:** Shows black granules and whitish mucinous material in the subcutaneous plane.

typical filamentous hyphae of the fungus (**Figure 3**). Fungal hyphae were cultured in Agar medium, showing the germ tube effect (**Figure 4**). Histopathology of the tissue showed typical features of Eumycetoma in the form of epithelioid granuloma with marked inflammatory response and micro-colonies of fungal hyphae (**Figure 5**). No separate bacterial culture and sensitivity was done.

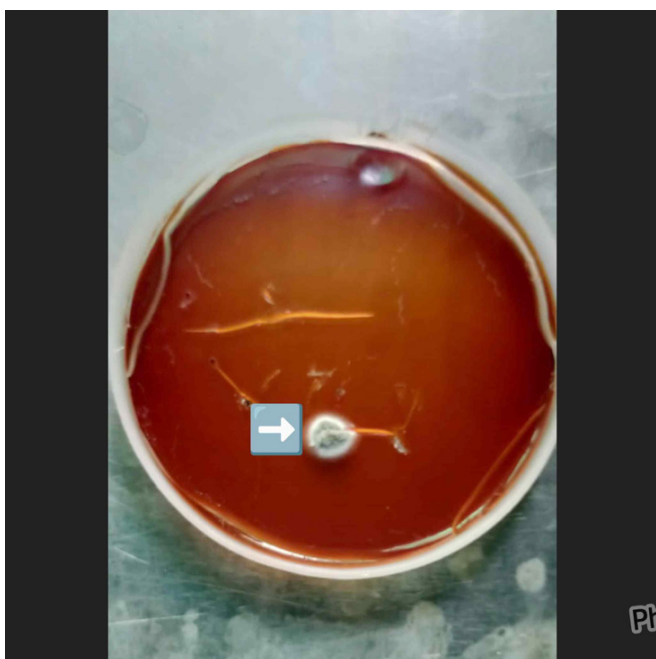
The wound healed without complications, and the swelling decreased to a moderate extent. Based on the confirmed



**Figure 3:** KOH wet mount microscopic examination of eumycetoma showing filamentous hyphae.



**Figure 5:** Histopathological picture of grains showing marked inflammatory response and hyperplasia surrounding the micro-colonies of fungus.



**Figure 4:** Agar plate Sabouraud medium showing the germ tube effect due to fungal growth.

diagnosis of eumycetoma, the patient was started on antifungal treatment with itraconazole 200 mg twice daily for 6 months. At the 15-month follow-up, the patient remained symptom-free, able to walk normally, and wear regular shoes. There has been no return of swelling, and no neurological or vascular impairments are present.

## DISCUSSION

Eumycetoma is an uncommon disease in India. In the early stages, it is misdiagnosed or diagnosed late, hence treated late or improperly. [5] Lack of suspicion of the condition

due to less familiarity with the condition, non-availability of diagnostic facilities, and lower incidence are other important clinical factors for late diagnosis. Diagnostic delay of up to 15 years has been reported. [6] The most common causes for Eumycetoma are *Mycetoma mycetomatis* and *M. grisea*, whereas the common bacteria causing Actinomycetoma are *Streptomyces somaliensis* and *Actinomadura madurae*. [7]

In late stages, the disease classically presents with a triad of painless subcutaneous mass, multiple sinuses, and discharge containing grains. Tendons and nerves are well preserved in the advanced stages, also due to adequate blood supply. Eighty-two percent of cases are seen in the foot, while 7% are reported in the hand. [8] Cases of Mycetoma on the scalp [9] and back have been reported, along with involvement of the brain and vertebra, respectively.

Mycetoma requires identification of the causative organism by various laboratory tests such as acid-fast staining, KOH (silver staining), PAS (periodic acid Schiff stain), GMS (Grocott's methenamine silver stain), and B&B (Brown and Brenn stain). Eumycetoma is positive for KOH Staining, PAS staining, and GMS Staining, and negative for acid-fast staining and B&B staining.

Actinomycetoma is negative for KOH, PAS, and GMS staining, but it is weakly positive for acid-fast staining and positive for Gram staining. On USG (Ultrasonography) examination, Eumycetoma is hyper-echogenic while Actinomycetoma is less echogenic. On X-rays of the part, bony cavities in Eumycetoma are few but larger with clear margins, as against multiple small cavities with indistinct margins seen in Actinomycetoma. There is a role of molecular polymerase chain reaction and molecular loop-mediated isothermal amplification in the diagnosis of Eumycetoma. Treatment for Eumycetoma is with antifungal drugs, whereas Actinomycetoma is treated by suitable antibiotics in the early stages.

Both conditions may need ablation of the part in cases of gross deformity associated with repeated uncontrolled infection and gross loss of function of the part.

A series of eight cases of subcutaneous fungal infection in upper and lower limbs presenting as cysts has been described. [10] Tenosynovitis of the flexor hallucis longus tendon and synovitis of the first MTP joint have been described following penetrating nail prick injury. [11]

## CONCLUSIONS

The present case presented as synovitis of the first MTP joint along with tenosynovitis of the EHL tendon. Fungal infection was considered as a differential diagnosis, as the swelling was in the foot for 2 years, and the patient was a field worker. The diagnosis was per-operatively suspected by the presence of coarse black granules in different pockets in the subcutaneous plane without any involvement of the tendon. The microbiological investigations of the wet KOH mount of the crystals and culture of hyphae on agar medium confirmed the diagnosis of Eumycetoma. Histopathological picture and culture further endorsed the diagnosis. The case was treated surgically with complete excision of the fungal granuloma and antifungal medications for a period of 6 months. The foot could be saved because the disease was diagnosed early, before the involvement of bone, and treated promptly.

## PATIENT CONSENT

Written informed consent was obtained from the patient for publication of this case report.

## AUTHORS' CONTRIBUTION

All authors have significantly contributed to the work, whether by following the case at the bedside, conducting literature searches, drafting, revising, or critically reviewing the article. They have given their final approval of the version to be published, have agreed with the journal to which the article has been submitted, and agree to be accountable for all aspects of the work.

## SOURCE OF FUNDING

None.

## CONFLICT OF INTEREST

None.

## REFERENCES

1. Welsh O, Vera-Cabrera L, Salinas-Carmona MC. Mycetoma. *Clin Dermatol.* 2007;25(2):195-202. <https://doi.org/10.1016/j.clindermatol.2006.05.011>
2. Pérez-Blanco M, Hernández-Valles R, Fernández-Zeppenfeldt G, Yegres F. [Mycetoma: Report of 3 cases in Falcón State, Venezuela]. *Invest Clin.* 1996;37(1):61-73.
3. Zijlstra EE, van de Sande WWJ, Welsh O, Mahgoub ES, Goodfellow M, Fahal AH. Mycetoma: A unique neglected tropical disease. *Lancet Infect Dis.* 2016;16(1):100-112. [https://doi.org/10.1016/s1473-3099\(15\)00359-x](https://doi.org/10.1016/s1473-3099(15)00359-x)
4. Gosselink C, Thomas J, Brahmabhatt S, Patel NK, Vindas J. Nocardiosis causing pedal actinomycetoma: A case report and review of the literature. *J Foot Ankle Surg.* 2008;47(5):457-462. <https://doi.org/10.1053/j.jfas.2008.04.009>
5. Emmanuel P, Dumre SP, John S, Karbwang J, Hirayama K. Mycetoma: A clinical dilemma in resource limited settings. *Ann Clin Microbiol Antimicrob.* 2018;17(1):35. <https://doi.org/10.1186/s12941-018-0287-4>
6. Veraldi S, Grancini A, Venegoni L, Merlo V, Guanziroli E, Menicanit C, et al. Mycetoma caused by *Aspergillus nidulans*. *Acta Derm Venereol.* 2016;96(1):118-119. <https://doi.org/10.2340/00015555-2144>
7. Verma P, Jha A. Mycetoma: Reviewing a neglected disease. *Clin Exp Dermatol.* 2019;44(2):123-129. <https://doi.org/10.1111/ced.13642>
8. Fahal AH, Shaheen S, Jones DHA. The orthopaedic aspects of mycetoma. *Bone Joint J.* 2014;96-B(3):420-425. <https://doi.org/10.1302/0301-620x.96b3.31421>
9. Welsh O, Morales-Toquero A, Vera-Cabrera L, Vazquez-Martinez O, Gómez-Flores M, Ocampo-Candiani J. Actinomycetoma of the scalp after a car accident. *Int J Dermatol.* 2011;50(7):854-857. <https://doi.org/10.1111/j.1365-4632.2011.04874.x>
10. Priyadharshini G, Varghese RG, Phansalkar M, Ramdas A, K A, G T. Subcutaneous fungal cyst masquerading as benign lesions - a series of eight cases. *J Clin Diagn Res.* 2015;9(10):EM01-EM04. <https://doi.org/10.7860/jcdr/2015/14157.6637>
11. Lui TH. Flexor hallucis longus tenosynovitis and first metatarsophalangeal synovitis after penetrating nail prick injury: Treated by zone 3 flexor hallucis longus tendoscopy and metatarsosesamoid arthroscopy. *Arthrosc Tech.* 2017;6(2):e427-e433. <https://doi.org/10.1016/j.eats.2016.10.020>